Hyperpolarized ^{3}He Magnetic Resonance Imaging following Oscillatory Positive Expiratory Pressure Treatment in GOLD stage II & III COPD

S Svenningsen[1,2], BN Jobse[1], A Hasany[1,4], N Kanhere[1,3], M Kirby[1,2], J Suggett[5], DG McCormack[4] and G Parraga[1,3]

[1]Imaging Research Laboratories, Robarts Research Institute; [2]Department of Medical Biophysics, [3]Graduate Program in Biomedical Engineering, [4]Division of Respirology, Department of Medicine, The University of Western Ontario, London, CANADA; [5]Trudell Medical International, London, CANADA

Introduction

- Airway clearance techniques are thought to help improve mucus clearance and dyspnea in chronic pulmonary diseases such as CF and bronchiectasis.
- The effect of positive expiratory pressure and oscillatory positive expiratory pressure (oPEP) in COPD is not well-understood.
- To test the effects of oPEP in COPD, a hand-held prototype device (Aerobika™, Trudell Medical International London CANADA) was evaluated in COPD ex-smokers.

Goal: To determine the effect of oPEP on pulmonary function, imaging biomarkers of airway function, St. George's Respiratory Questionnaire (SGRQ) and a mucous clearance questionnaire.

Hypothesis

- oPEP use results in significantly improved mucous clearance and symptom scores in COPD ex-smokers

Research Objective

- To evaluate the safety and efficacy of four-times daily oPEP over 4 weeks in COPD ex-smokers using pulmonary function tests (PFTs), hyperpolarized ^{3}He magnetic resonance imaging (MRI), six minute walk test (6MWT), SGRQ, and a validated symptom diary[1].

Methods

Study Subjects and Design

- 17 COPD ex-smokers were randomized to 4 weeks of oPEP or no therapy in a cross-over study.

Cross-over

Week	0	1	2	3	4	5	6	7	8
Visit	1		2		3		4		5
Group 1	ON-oPEP					OFF-oPEP			
Group 2	OFF-oPEP					ON-oPEP			

PFT's, 6MWD, SGRQ

^{3}He MRI

Study Subjects and Design

- Pulmonary function tests (spirometry, plethysmography, D_{LCO}) were acquired on an *EasyOne* spirometer (ndd Medizintechnik AG, Zurich, CH) according to ATS guidelines.
- 6MWT, SGRQ, and mucous clearance symptom questionnaire were acquired at each visit.

Image Acquisition and Analysis

- **MRI** performed on 3T Discovery 750MR (GEHC, Milwaukee, USA)
- ^{3}He MRI ventilation defect percent **(VDP)**[2] generated for images acquired after a 15s breath-hold (FRC+1L).
- 14 subjects completed the study and two cases are presented – a single self-reported non-responder and self-reported responder.

Results

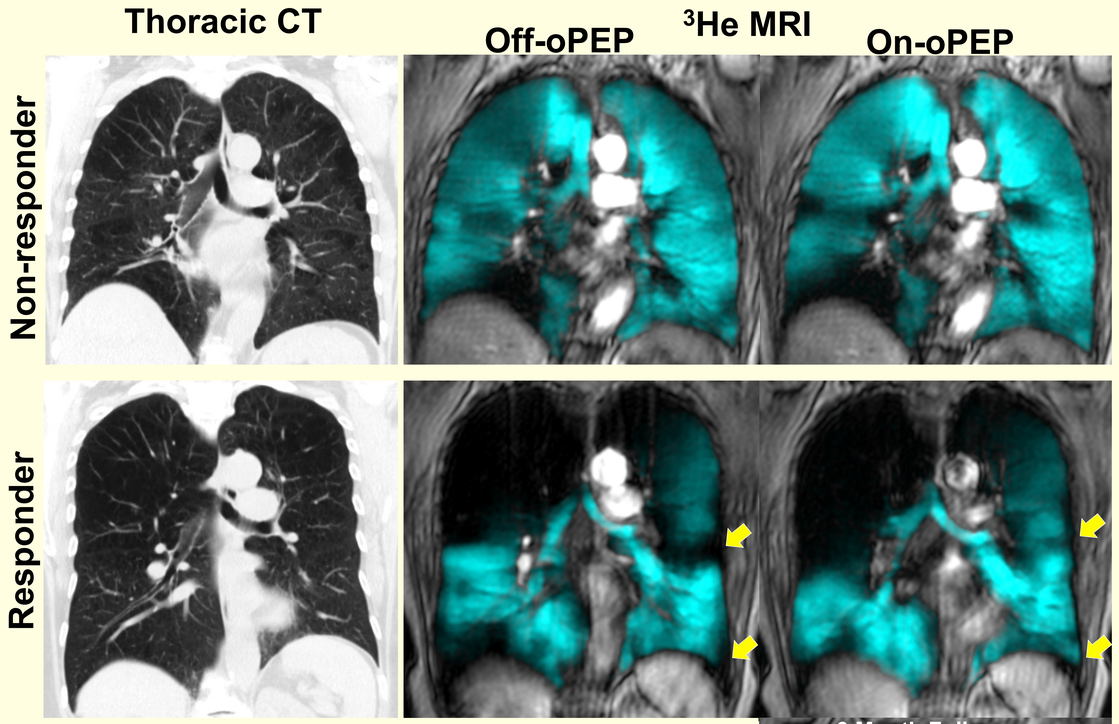

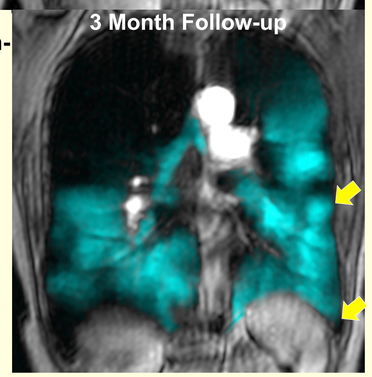

Figure 1. Center slice CT and ^{3}He MRI in a self-reported non-responder and responder to 4 weeks oPEP

Table 1. Demographic Data

	Non-responder	Responder
Age (years)	69	74
Gender	F	F
GOLD Stage	II	III
Pack-years	52	42

Table 2. Pulmonary Function, Symptoms and Imaging Data

	Non-responder		Responder	
	Off-oPEP	On-oPEP	Off-oPEP	On-oPEP
FEV_1 ($\%_{pred}$)	62	58	44	43
FVC ($\%_{pred}$)	101	99	79	83
FEV_1/FVC ($\%_{pred}$)	47	45	43	40
RV ($\%_{pred}$)	117	117	176	162
TLC ($\%_{pred}$)	111	108	121	114
RV/TLC ($\%_{pred}$)	109	108	138	139
D_{LCO} ($\%_{pred}$)	46	35	30	27
6MWD (m)	472	466	394	390
SGRQ	43	49	45	35
Cough Frequency	Rare	Rare	Rare	Frequent
Dyspnea	Moderate	Moderate	Moderate	Moderate
Ease Bringing up Sputum	No Change	Slightly Worse	Slightly Worse	Moderate Improvement
^{3}He VDP (%)	15	20	34	32
RA -950HU (%)	17	-	21	-

Discussion

- In a single self-reported responder, SGRQ total score and ease of mucous clearance was improved, cough frequency was increased and FVC, RV, TLC and RV/TLC were also improved suggesting improved gas trapping and this was consistent with a very modest improvement in ^{3}He MRI VDP.
- In a single self-reported non-responder, there were no improvements in SGRQ, dyspnea or ease of bringing up sputum and there was no change in any PFT measurement, and ^{3}He MRI increased or worsened (15%-20%).

Conclusions

- In this pilot, proof-of-concept study, self-administered oPEP therapy over 4 weeks variably affected lung volumes, VDP and symptoms in two cases with stable advanced COPD.
- One COPD ex-smoker case exhibited clear improvements in spirometry and plethysmography measurements, mucous clearance and SGRQ, whereas the other case showed no or little change during the treatment period.
- Future work will involve careful patient phenotyping using MRI and CT to help stratify subjects to oPEP therapy and to better understand therapy responses.
- Results in all subjects are currently being evaluated to determine the effect of 4 weeks oPEP in 14 COPD ex-smokers who completed therapy.

For two COPD ex-smokers, one a self-reported non-responder and the other a self-reported responder to oPEP, there were changes in PFTs, ^{3}He MRI VDP, SGRQ and ease in bringing up sputum that were in agreement with self-reported response.

References

1. **Petty TL.** The National Mucolytic Study: Results of a Randomized, Double-Blind, Placebo-Controlled Study of Iodinated Glycerol in Chronic Obstructive Bronchitis. *Chest.* 1990 Jan;97(1):75-83.
2. **Kirby M *et al*.** Hyperpolarized ^{3}He magnetic resonance functional imaging semi-automated segmentation. *Acad Radiol.* 2012 Feb; 19(2):141-52.

Acknowledgements

We thank S. Halko, CCRC, RPT, and D. Buchanan, BSc, for clinical coordination and T. Szekeres, RMT, for MRI of research volunteers. We gratefully acknowledge Grant-in-aid funding from Trudell Medical International for this research.

Contact: ssvenningsen@robarts.ca, gparraga@robarts.ca